

MINI ASD CLOSURE IN DEXTROCARDIA WITH SITUS INVERSUS BY LALT APPROACH- A SURGICAL CHALLENGE

Dr. Thakut Gowtham MS¹, Dr. Aneesh Lawande MS¹, Dr. Herin Patel M.Ch², Dr. Archit Patel M. Ch³, Dr. Kartik Patel M. Ch³

1.Resident, 2 .Assistant Professor, 3. Associate Professor, Department of Cardiovascular & Thoracic Surgery,
U. N. Mehta Institute of Cardiology and Research Center, Civil Hospital Campus, Asarwa, Ahmedabad, Gujarat, India, 380016.

Corresponding Author :

Dr. Thakut Gowtham Mch Resident, CVTS • dr.thakutgowtham@gmail.com

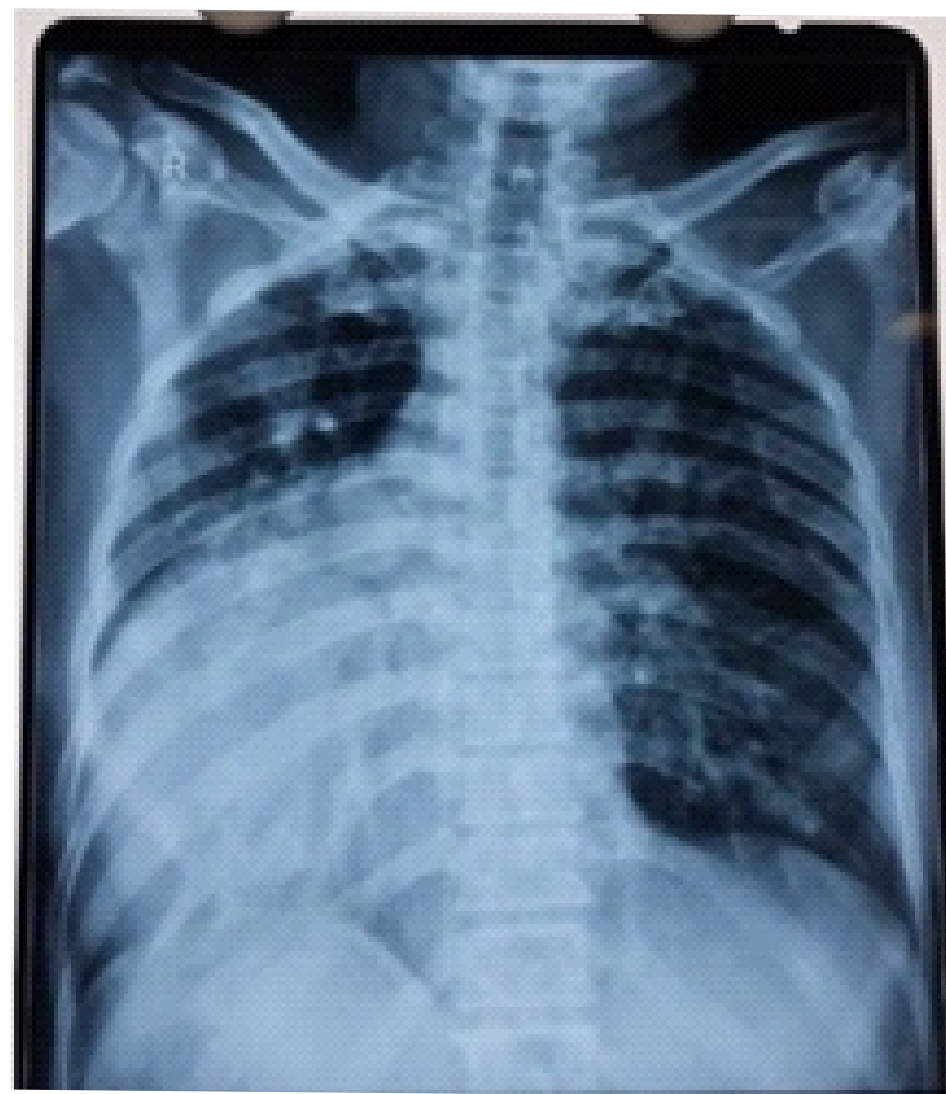Department of Cardiovascular & Thoracic Surgery, UNMICRC

INTRODUCTION

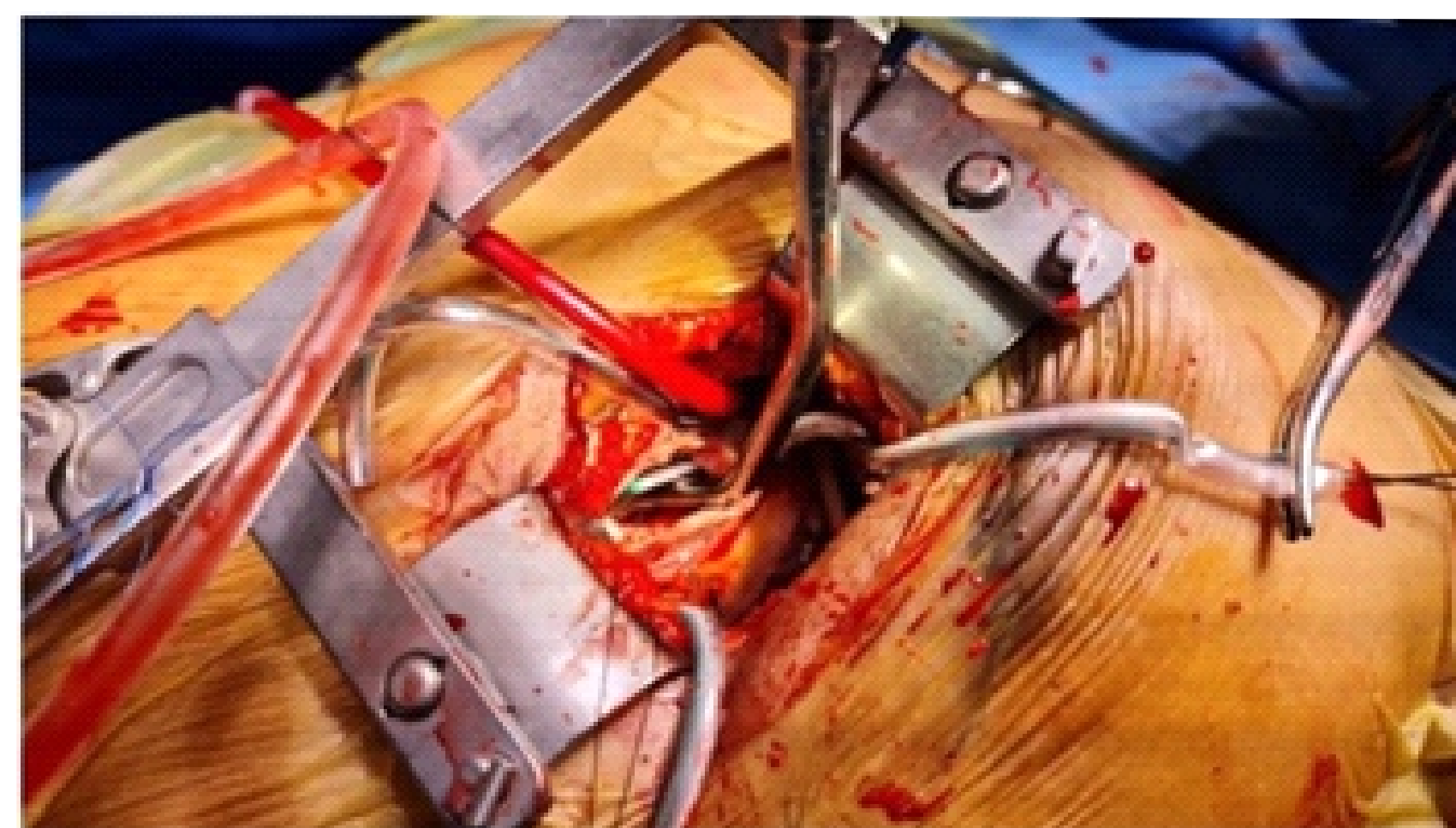ASD is one of the most common congenital heart diseases found in adults. Dextrocardia with situs inversus is the most common variety of dextrocardia [1]. ASD is a relatively rare subset among patients with situs inversus dextrocardia with concordant AV connection [1,2] and a minimally invasive approach in dextrocardia has yet to be standardized. The present case study describes a case surgical closure of ostium secundum ASD by left mini-thoracotomy approach in patient with dextrocardia and situs inversus.

CASE REPORT

A 44-year female patient presented to our hospital with a history of dyspnoea on exertion for 3 months (NYHA 2), and on transthoracic echocardiography showed Dextrocardia with 26 mm ostium secundum atrial septal defect with left to right shunt with deficient IVC rim, mild TR and normal biventricular function. Chest radiograph showing position of heart in right hemithorax with apex pointing towards right (figure 1A). Contrast-enhanced computed tomography (CECT) showed cardiac situs-dextrocardia and visceral situs-inversus with no systemic or pulmonary anomalies. The patient was intubated with a single-lumen endotracheal tube, A small 4 to 5-cm left anterolateral thoracotomy (LALT) was used to enter the thorax through 3rd intercostal space (ICS) which was corresponding to mid of right atria. An intercostal rib spreader was used for additional exposure and we did not perform rib transection/resection (figure 1B). Moderate, hypothermic Cardiopulmonary bypass (CPB) was established by percutaneous cannulation of the left common femoral artery and left common femoral vein (dual stage venous cannula; Medtronic, Bio- MedicusTM). Pericardial stays taken, which enhances the exposure of right atrium. The external aortic cross-clamp was inserted via the 2nd ICS at the left midaxillary line. Antegrade cardioplegia was delivered directly into the aortic root.



A. Preoperative Chest X-ray



B. Intraoperative picture showing Atrial Septal Defect

Figure 1:

A) Pre-operative chest x-ray showing dextrocardia.

B) Intra-operative picture showing the atrial septal defect.

An oblique incision is made at the base of right atrial appendage allowing a direct examination of ASD. The defect was approximately 40 mm, with an oval shape ostium secundum with a deficient IVC rim. ASD closed with a PTFEE patch. Epicardial pacing wires were placed. Under TEE control, De-airing of the left atrium and left ventricle was performed. After de-clamping the aorta and weaned off CPB without supports.

LALT incision was closed in a routine fashion. The patient was in ICU for one day and discharged on postoperative day 3. On follow-up after 1 month, the patient was carrying her normal routine activities and her 2D ECHO findings were normal.

DISCUSSION

Dextrocardia, a rare cardiac malposition, is defined as the positioning of the heart in the right hemithorax, with the apex pointing to the right. This was first described by Fabricius in 1606 [1].

Patient selection and preoperative planning:

A lot of minimally invasive approaches in levocardia with situs solitus have been described for surgical closure of ASD being partial sternotomy [3-5], trans xiphoid approach [6], right anterolateral [7], right axillary, right thoracotomy approaches, but there are no reports or guidelines for surgical closure of ASD in dextrocardia with situs inversus. In general, the most important aspect of the operation is exposure because the intervention itself does not differ from that in patients with levocardia with situs solitus. The key points are the surgeon's position, the surgical incision, exposure of the right atrium, and the incision over the right atrium.

These decisions should be made preoperatively, based on imaging. Therefore, it is to be thoroughly evaluated regarding their suitability for the LALT approach preoperatively.

Dextrocardia is usually associated with congenital anomalies, we wanted to evaluate preoperatively by performing a computed tomography (CT) scan with contrast enhancement of the chest and rule out juxtapose appendage on the left side, venous congenital anomalies like interrupted IVC in the infra hepatic part which might require modification of venous cannulation techniques, RSVC, dual SVC, arterial anomalies, and PAOD.

In the case of juxtaposed atrial appendage on the left side, the RA would be small comparatively, and performing a mini-ASD repair would be difficult, as this could not be assessed on the 2D echo as in our case because RA would be retrosternal and could not be assessed properly, therefore it has to be ruled out preoperatively.

The reported exclusion criteria for minimally invasive ASD closure by RALT are pathological calcification of the ascending aorta (soft plaques), history of pleuritis, or a deep chest [5,7] could be the same for LALT. Intraoperatively, in our case, good exposure is necessary, due to the retrosternal location of RA. To achieve this, pericardiotomy was done 2 cm above the phrenic nerve, and pericardial retraction sutures were placed below the phrenic nerve, and near the junction of the pulmonary vein and RA, these stays were pulled towards the surgeon and were fixed to the chest wall, lateral to the incision (figure 2A).

In dextrocardia the lie of RA is more medial to lateral, therefore the incision over the right atrium is given more oblique and downwards when compared to conventional RALT mini ASD closure. (figure 2A). To increase the exposure of atrial septal defect, the venous cannula was looped using an umbilical tape and pulled downwards. (Figure 2B, C)

With ASD device closure procedures becoming more popular, it is important to offer alternative surgical operations that come with both, known durability and a minimized surgical trauma with satisfactory cosmesis [7,8,9,10]. As demonstrated in this manuscript, the mini-ASD closure LALT procedure seems to complement both of these requirements.

ASD repair in a patient with dextrocardia with situs inversus, a mini-thoracotomy approach was performed by cannulating the left femoral artery and vein. Under moderate hypothermia, antegrade cardioplegia was administered to arrest the heart. This approach was not associated with any limitations in a patient with dextrocardia with situs inversus.

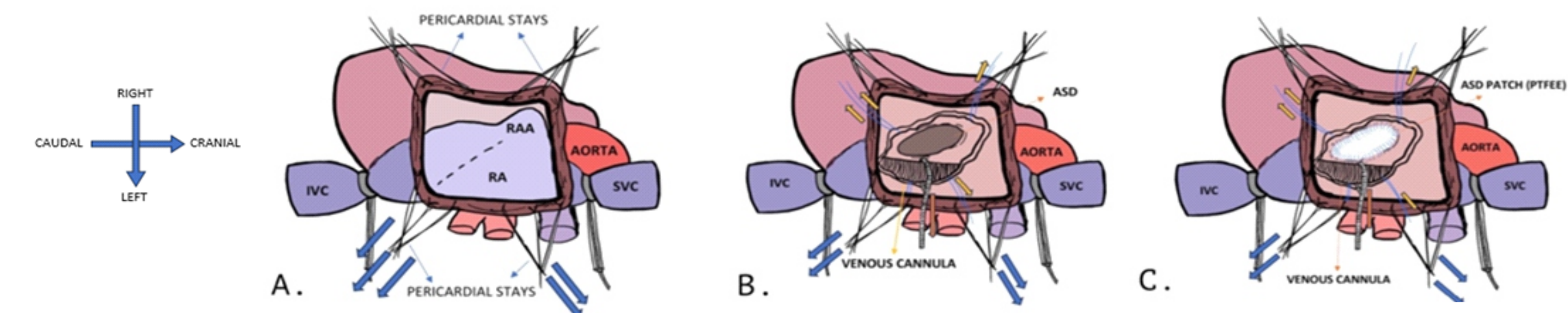


Figure 2:

A) Diagram showing pericardial stays and oblique incision over RA for good exposure,

B) Diagram showing OS ASD with retraction of the venous cannula for good exposure of ASD.

C) Diagram showing ASD repair with PTFEE patch.

CONCLUSIONS

- There are several implications for surgical practice: In patients with dextrocardia requiring cardiac surgery, it is important to diligently plan the appropriate cannulation technique and surgical strategy to avoid major errors due to the variable anatomy and the mirror imaging of the structures.
- The advantages of mini ASD closure LALT can be combined with accelerated mobilization, reduce post-operative pain, improved chest wall stability, good cosmetic results, and reduced length of hospital stay.
- The LALT approach allows the sternum and ribs to be preserved in their entity. A sternum-sparing procedure decreases the potential of bleeding as well as the need for transfusions with the associated complications.

REFERENCES

1. Bohun CM, Potts JE, Casey BM, Sandor GG. A population- based study of cardiac malformations and outcomes associated with dextrocardia. Am J Cardiol 2007; 100:305-309.
2. Naveen Garg, B L Agarwal, Nitin Modi, S Radhakrishnan, Nakul Sinha. Dextrocardia: an analysis of cardiac structures in 125 patients. Int J Cardiol 2003; 88: 143-155
3. Bichell DP, Geva T, Bacha EA, Mayer JE, Jonas RA, del Nido PJ. Minimal access approach for the repair of atrial septal defect: the initial 135 patients. Ann Thorac Surg. 2000; 70:115-8.
4. Konstantinov IE, Buratto E. Atrial septal defect closure via ministernotomy in children. Heart Lung Circ. 2021;30: e98-100.
5. Black MD, Freedom RM. Minimally invasive repair of atrial septal defects. Ann Thorac Surg. 1998; 65:765-7.
6. Barbero-Marcial M, Tanamati C, Jatene MB, Atik E, Jatene AD. Transxiphoid approach without median sternotomy for the repair of atrial septal defects. Ann Thorac Surg. 1998; 65:771-4.
7. Vida VL, Tessari C, Fabozzo A, Padalino MA, Barzon E, Zucchetta F, et al. The evolution of the right anterolateral thoracotomy technique for correction of atrial septal defects: cosmetic and functional results in prepubescent patients. Ann Thorac Surg. 2013; 95:242-7.
8. Dave HH, Comber M, Solinger T, Bettex D, Dodge-Khatami A, Pr^etre R. Mid- term results of right axillary incision for the repair of a wide range of congenital cardiac defects. Eur J Cardiothorac Surg. 2009; 35:864-70.
9. Dabritz S, Sachweh J, Walter M, Messmer BJ. Closure of atrial septal defects via a limited right anterolateral thora- cotomy as a minimal invasive approach in female patients. Eur J Cardiothor Surg 1999; 15:18-23.
10. Lancaster LL, Mavroudis C, Rees AH, Slater AD, Ganzel BL, Gray LA, Jr. Surgical approach to atrial septal defect in the female. Right thoracotomy versus sternotomy. Am Surg